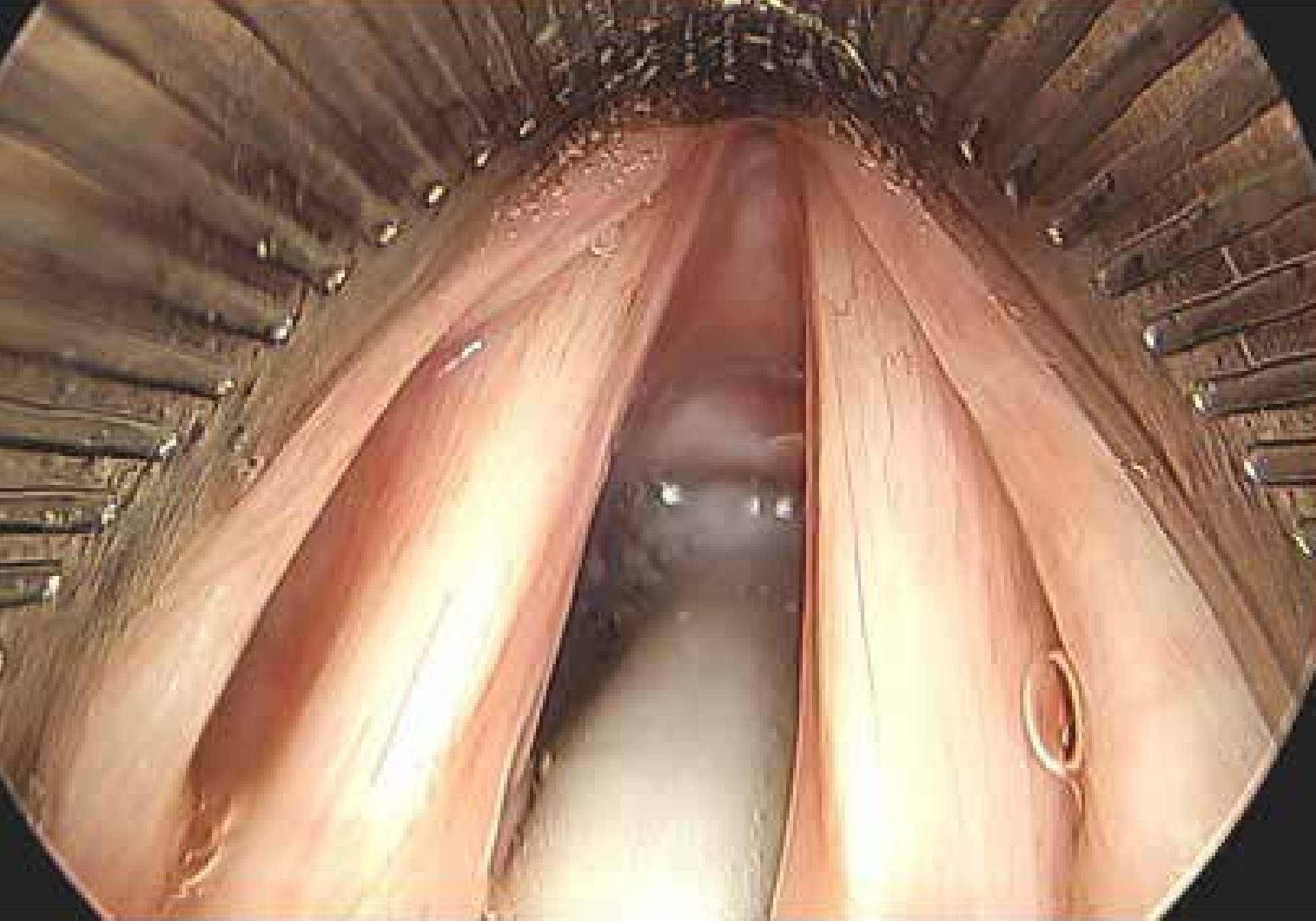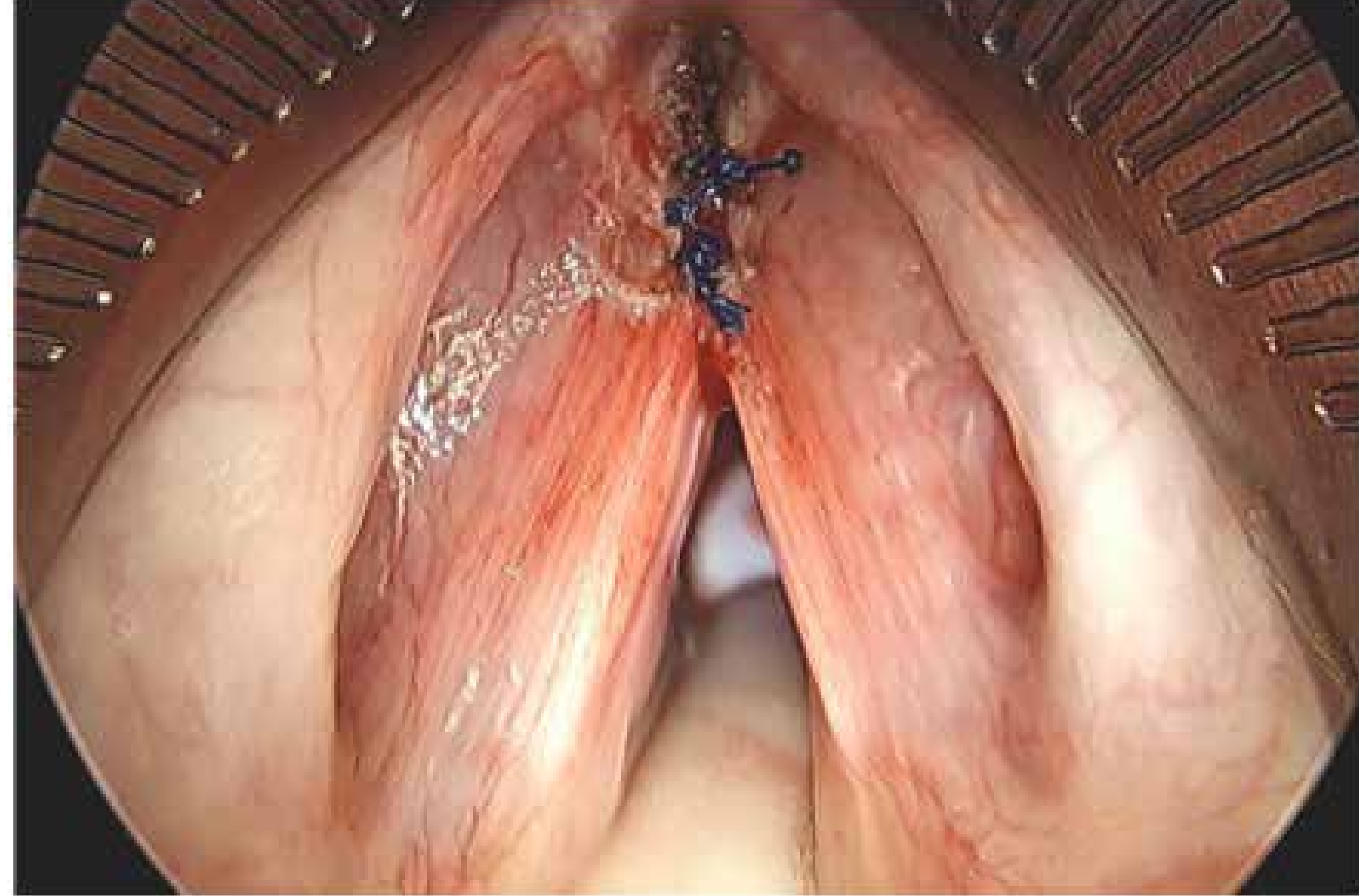


**1a**



**1b**

**Figure 1a and 1b.** Intraoperative direct laryngoscopy before (a) and after (b) endoscopic feminization laryngoplasty.